

# 学位論文

Clinical Features of Treated and Untreated Type 1  
Idiopathic Macular Telangiectasia Without the Occurrence  
of Secondary Choroidal Neovascularization Followed for  
2 Years in Japanese Patients

香川大学大学院医学系研究科  
分子情報制御医学専攻

逢坂理恵

# CLINICAL FEATURES OF TREATED AND UNTREATED TYPE 1 IDIOPATHIC MACULAR TELANGIECTASIA WITHOUT THE OCCURRENCE OF SECONDARY CHOROIDAL NEOVASCULARIZATION FOLLOWED FOR 2 YEARS IN JAPANESE PATIENTS

RIE OSAKA, MD, CHIEKO SHIRAGAMI, MD, AOI ONO, MD, MAMORU KOBAYASHI, MD, YUKARI TAKASAGO, MD, AYANA YAMASHITA, MD, AKITAKA TSUJIKAWA, MD

**Purpose:** To evaluate the clinical features of Type 1 idiopathic macular telangiectasia (IMT) followed up for 2 years.

**Methods:** Forty-nine patients with unilateral Type 1 IMT were examined. Thirty-one IMT eyes were treated with direct laser photocoagulation and/or intravitreal bevacizumab; the remaining 18 eyes, with good vision or slight macular edema, were untreated. Changes in best-corrected visual acuity and central retinal thickness between baseline and 24 months after the initial visit were examined.

**Results:** Of 49 eyes, nine were treated with direct laser photocoagulation, 12 with laser photocoagulation and intravitreal bevacizumab, 10 with intravitreal bevacizumab monotherapy, whereas 18 did not receive any treatment. The mean logarithm of the minimum angle of resolution best-corrected visual acuity was  $0.20 \pm 0.19$  (median, 20/29) and  $0.13 \pm 0.22$  (median, 20/25) at baseline and 24 months, respectively ( $P = 0.023$ ). The mean central retinal thickness was  $375.0 \pm 94.5 \mu\text{m}$  and  $315.3 \pm 78.5 \mu\text{m}$  at baseline and 24 months, respectively ( $P < 0.001$ ). Retinal vein occlusion and retinal macroaneurysm occurred in six eyes and one eye, respectively, during follow-up.

**Conclusion:** Treatment with laser photocoagulation and/or intravitreal bevacizumab may be effective for Type 1 IMT, 36.7% of IMT eyes required no treatment over a 2-year follow-up, and other retinal vascular events were not uncommon.

RETINA 38:S114–S122, 2018

Idiopathic macula telangiectasia (IMT) is characterized by retinal capillary vessel dilation. In 1982, Gass and Owaka proposed a classification of IMT, termed idiopathic juxtafoveal retinal telangiectasia.<sup>1</sup> In 2006, Yannuzzi et al<sup>2</sup> classified three types: Type 1 IMT (aneurysmal telangiectasia), Type 2 IMT (perifoveal telangiectasia), and Type 3 IMT (occlusive telangiectasia).

Type 1 IMT is unilateral and relatively common in Japanese men.<sup>3</sup> It predominantly occurs in middle-aged men and is typically located in the temporal half of the macula. The condition may lead to visual loss

because of the occurrence of macular edema with hard exudates. Telangiectasia is generally confined unilaterally in the perifoveal area, 1 to 2 discs in diameter, involving equivalent areas superior and inferior to the horizontal raphe. Multiple, venular, and arteriolar aneurysms can occur in cases of superficial ischemia and lipid deposition. Visual loss is mainly caused by macular edema and hard exudation.<sup>3,4</sup> There is no established treatment for Type 1 IMT. Although laser photocoagulation (LP), sub-Tenon's capsule injection of triamcinolone acetonide, dexamethasone intravitreal implant, and intravitreal anti-vascular endothelial

growth factor (VEGF) have been proposed as potentially effective treatment procedures,<sup>5-10</sup> to the best of our knowledge, only case reports of short-term observations have been published.

Moreover, the pathogenesis, long-term ocular adverse events, and relationship with systemic medical history of Type 1 IMT remain unclear. Therefore, the aim of this retrospective case series was to examine the clinical features of treated (LP and/or intravitreal anti-VEGF) and untreated Type 1 IMT eyes over a 2-year follow-up period.

## Methods

### *Study Design and Participants*

This study was approved by the Ethics Committee at Kagawa University Faculty of Medicine and conducted in accordance with the tenets of the Declaration of Helsinki. In this retrospective case series, clinical records and photographic files from the Kagawa University Hospital were reviewed to identify patients diagnosed with Type 1 IMT between November 2007 and April 2012.

All identified patients (n = 49) underwent best-corrected visual acuity (BCVA) examinations, fluorescein and indocyanine angiography (HRA2; Heidelberg Engineering, Heidelberg, Germany), fundus photography (Optos 200Tx imaging system; Optos PLC, Dunfermline, United Kingdom), and optical coherence tomography (Spectralis HRA + OCT; Heidelberg Engineering).

All eyes of 49 patients with Type 1 IMT were treatment naive, with retinal microvascular telangiectasia, parafoveal venular and arteriolar aneurysms, superficial ischemia, cystoid macula edema (CME),

---

From the Department of Ophthalmology, Kagawa University Faculty of Medicine, Kagawa, Japan.

C. Shiragami received financial support from Bayer (Osaka, Japan) and Novartis (Tokyo, Japan). A. Tsujikawa received financial support from Pfizer (Tokyo, Japan), Bayer (Osaka, Japan), Novartis (Tokyo, Japan), Santen (Osaka, Japan), Senju (Osaka, Japan), Alcon (Tokyo, Japan), Nidek (Gamagori, Japan), AMO Japan (Tokyo, Japan), Hoya (Tokyo, Japan), Kowa (Nagoya, Japan), Sanwa Kagaku (Nagoya, Japan), and the Ministry of Health Labour and Welfare of Japan, and Japan Society for the Promotion of Science (Tokyo, Japan). None of the remaining authors has any conflicting interests to disclose.

This is an open-access article distributed under the terms of the Creative Commons Attribution-Non Commercial-No Derivatives License 4.0 (CCBY-NC-ND), where it is permissible to download and share the work provided it is properly cited. The work cannot be changed in any way or used commercially without permission from the journal.

Reprint requests: Chieko Shiragami, MD, Department of Ophthalmology, Kagawa University Faculty of Medicine, 1750-1 Ikenobe Miki-cho, Kagawa 761-0793, Japan; e-mail: chappi@kms.ac.jp

and lipid deposition observed with fundus color, angiographic photographs, and optical coherence tomography. Patients with secondary macular telangiectasia (e.g., venous occlusion, diabetic retinopathy, and Coat disease) and neovascular maculopathy (e.g., age-related macular degeneration, retinal angiomatous proliferation, pathologic myopia, and angioid streaks) were excluded.

At the initial visit, eyes with a Snellen BCVA of 20/33 or less or a central retinal thickness (CRT) of at least 350  $\mu\text{m}$  were treated, whereas the remaining eyes were observed without treatment. As the initial treatment, a focal Argon LP was performed on the perifoveal area about the central avascular area of the fovea, targeting the retinal microaneurysm (MA). Laser photocoagulation was performed using a yellow wavelength, power of 80 mW to 120 mW, spot size of 50  $\mu\text{m}$  to 150  $\mu\text{m}$ , and duration of 0.15 seconds to 0.2 seconds using Novus Varia (Lumenis, Santa Clara, CA). In cases where laser treatment would be difficult due to the proximity of the retinal MA to the fovea, intravitreal bevacizumab (IVB) (Avastin; Genentech, San Francisco, CA) of 1.25 mg was administered.

### *Study Procedures and Examinations*

Changes in BCVA and CRT were examined in all patients 1 month after treatment. If the BCVA worsened, and the CRT did not reduce, additional treatments were administered. If the CRT reduced, patients were examined monthly and retreated, if necessary. The retreatment criteria were as follows: BCVA reduction by more than 2 lines, CRT increased by more than 50  $\mu\text{m}$ , and occurrence of persistent CME.<sup>11</sup> All patients were fully informed about the off-label use of bevacizumab and its potential side effects. In addition, patients' systemic history and occurrence of any retinal vascular adverse events during the follow-up period were examined.

### *Statistical Analyses*

A Statistical analysis of changes in the logarithm of the minimum angle of resolution (logMAR) BCVA and CRT between baseline (initial visit) and 24 months was performed by paired *t* test. Longitudinal analysis using a generalized estimating equation was also conducted to evaluate the influence of retinal vascular events. Potential confounding factors, including sex, initial CRT and logMAR BCVA, and systemic medical history (such as cerebral infarction and myocardial infarction) were included in the modeling. Significant influencing factors of retinal vein occlusion (RVO) were examined using Fisher's exact probability test. Statistical analysis was used with SPSS software

version 20.0 (IBM Corp, Armonk, NY). *P* values <0.05 were considered statistically significant.

## Results

### Patients

Forty-nine treatment-naïve patients with unilateral Type 1 IMT (29 men, 20 women; mean  $\pm$  SD age, 70.5  $\pm$  11.6 years) were included in this study. The follow-up periods exceeded 24 months in all patients. Patient baseline characteristics are summarized in Table 1. At baseline, all eyes showed prominent parafoveal capillaries, MAs, and CME. For all patients, fluorescein angiography showed late leakage surrounding the fovea, whereas optical coherence tomography revealed CME. Of 49 eyes, 9 were treated with LP monotherapy, 12 with LP and IVB, 10 with IVB monotherapy, whereas the remaining 18 eyes did not receive any treatment.

### Systemic Medical History of Patients With Type 1 Idiopathic Macula Telangiectasia

The systemic medical histories were as follows: blood hypertension in 22 patients (44.9%), hyperlipidemia in 13 patients (26.5%), cerebral infarction in 7 patients (14.3%), and myocardial infarction in 4 patients (8.2%) (Table 1).

### Change in logMAR Visual Acuity

The mean logMAR BCVA was 0.20  $\pm$  0.19 (median, 20/29) and 0.13  $\pm$  0.22 (median, 20/25) at baseline and 24 months (*P* = 0.023), respectively (Table 2). The mean logMAR BCVA according to the treatment option was as follows: LP alone, 0.23  $\pm$  0.18 (median, 20/33) and 0.16  $\pm$  0.14 (median, 20/31); LP with IVB, 0.32  $\pm$  0.18 (median, 20/40) and 0.25  $\pm$  0.23 (median, 20/33); IVB alone, 0.20  $\pm$  0.11

(median, 20/33) and 0.16  $\pm$  0.32 (median, 20/25); and nontreatment, 0.11  $\pm$  0.16 (median, 20/22) and 0.03  $\pm$  0.13 (median, 20/21), at baseline and 24 months, respectively. In each treatment group, there were no significant differences between baseline and 24 months (Figure 1). The logMAR BCVA improved in seven eyes (14%; LP alone, one eye; IVB with LP, 4 eyes; nontreatment, 2 eyes), maintained in 41 eyes (84%; LP alone, 8 eyes; IVB with LP, 8 eyes; IVB alone, 9 eyes; nontreatment, 16 eyes), and decreased in one eye (2%; IVB alone), when a logMAR BCVA >0.3 was defined as a meaningful change.

### Change in Central Retinal Thickness

The mean CRT of treated eyes was 375.0  $\pm$  94.5  $\mu$ m and 315.3  $\pm$  78.5  $\mu$ m at baseline and 24 months (*P* < 0.001), respectively (Table 2). According to the treatment option, the mean CRT was as follows: LP alone, 350.2  $\pm$  62.6  $\mu$ m and 296.4  $\pm$  90.1  $\mu$ m; LP with IVB, 485.6  $\pm$  97.3  $\mu$ m and 389.8  $\pm$  88.3  $\mu$ m; IVB alone, 362.8  $\pm$  49.9  $\mu$ m and 291.2  $\pm$  56.9  $\mu$ m; nontreatment, 321.1  $\pm$  60.9  $\mu$ m and 288.2  $\pm$  34.7  $\mu$ m, at baseline and 24 months, respectively. The CRT of the eyes treated with IVB monotherapy, and IVB followed by LP, was significantly reduced (*P* = 0.012 and *P* = 0.020, respectively) (Figure 2), whereas the CRT in the nontreatment group had a reduced tendency at 24 months compared with baseline (*P* = 0.055).

### Change in Cystoid Macular Edema

In the treatment group, CME was reduced in 24 eyes (LP alone, 5 eyes; IVB with LP, 10 eyes; IVB alone, 9 eyes) and disappeared in 15 eyes (LP alone, 7 eyes; IVB with LP, 4 eyes; IVB alone, 4 eyes). In the nontreatment group, although CME was reduced in three eyes and maintained in nine eyes, these eyes maintained good visual acuity (VA).

Table 1. Baseline Characteristics of Patients With Type 1 Idiopathic Macula Telangiectasia

	Total	Treatment	Nontreatment
No. of patients	49	31	18
Age, years, (SD)	70.5 (11.6)	69.9 (12.4)	71.6 (10.2)
Sex			
Men (%)	29 (59.2)	17 (54.8)	12 (66.7)
Women (%)	20 (40.8)	14 (45.2)	6 (33.3)
Median BCVA	20/29	20/33	20/22
CRT, $\mu$ m, (SD)	375.0 (94.5)	406.3 (97.2)	321.1 (60.9)
Anamnesis			
Hypertension (%)	22 (44.9)	13 (41.9)	9 (50.0)
Hyperlipidemia (%)	13 (26.5)	4 (12.9)	9 (50.0)
Cerebral infarction (%)	7 (14.3)	3 (9.7)	4 (22.2)
Myocardial infarction (%)	4 (8.2)	3 (9.7)	1 (5.6)

Table 2. Mean Visual Acuity and Central Retinal Thickness at Baseline and 24 Months

	Total	<i>P</i>	Treatment	<i>P</i>	Nontreatment	<i>P</i>
LogMAR BCVA ± SD (median Snellen acuity)						
Baseline	0.20 ± 0.19 (20/29)	0.023*	0.26 ± 0.18 (20/33)	0.256*	0.11 ± 0.16 (20/22)	0.108*
24 months	0.13 ± 0.22 (20/25)		0.19 ± 0.24 (20/29)		0.03 ± 0.13 (20/21)	
CRT, μm ± SD						
Baseline	375.0 ± 94.5	<0.001*	406.3 ± 97.2	0.003*	321.1 ± 60.9	0.055*
24 months	315.3 ± 78.5		331.0 ± 92.1		288.2 ± 34.7	

\*Paired *t* test was used for statistical analysis between baseline and 24 months. *P* value <0.05 was set as statistical significance.

#### Number of Intravitreal Bevacizumab Administrations

The mean number of IVB administrations in all 22 patients was  $2.0 \pm 1.5$ . Of the 22 eyes treated with IVB, in the LP with IVB group, bevacizumab was administered  $1.8 \pm 1.7$  times, and in IVB alone group,  $2.1 \pm 1.0$  times. There were no significant differences in the number of IVB administrations about age, BCVA, and CRT at baseline.

#### Retinal Vascular Events During the Follow-up Period

Retinal vascular events occurred in seven eyes during the 2-year observational period (14.3%). RVO occurred in six eyes, and retinal macroaneurysm was present in one eye. The onset time of retinal vascular events varied from 7 months to 24 months ( $21.3 \pm 4.9$  months) after baseline. RVO occurred in 6 patients (one man and five women) with a mean age of

$72.8 \pm 9.6$  years, mean logMAR BCVA at baseline of  $0.28 \pm 0.10$  (median, 20/36), and mean CRT at baseline of  $427.7 \pm 141.0$  μm. Three of these patients were treated with IVB followed by LP, two with LP alone, whereas the other patient received no treatment.

Medical histories comprised blood hypertension in one patient, blood hypertension and cerebral infarction and myocardial infarction in the second, and both hypertension and cerebral infarction in the third patient. The first and second patients were treated with LP, and the third patient was treated with IVB followed by LP. The fourth patient, who received no treatment, had hypertension, cerebral infarction, and hyperlipidemia. In the remaining three patients (one of them was the patient with MA), there were no medical histories of IVB treatment followed by LP.

The case complicated with retinal macroaneurysm involved a 68-year-old man treated with IVB followed by LP. This patient's logMAR BCVA and CRT were 20/100 and 600 μm at baseline, respectively.

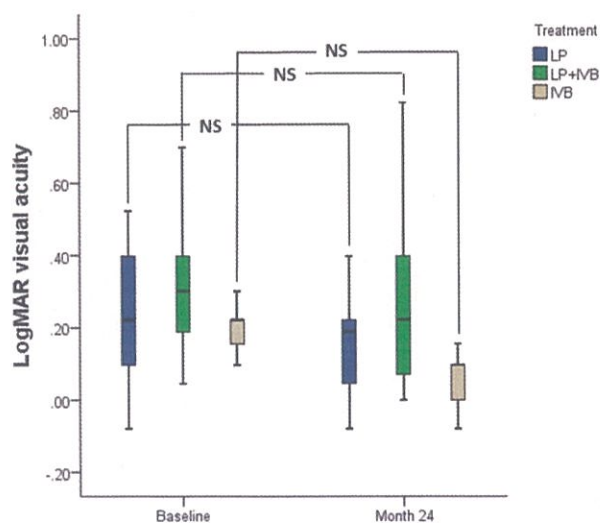


Fig. 1. Box plot of logMAR VA of Type 1 IMT eyes according to the treatment option at baseline and 24 months. In each treatment option for Type 1 IMT, mean logMAR VA is not significantly improved at 24 months. The mean is the horizontal line, the boxes are the first/third quartiles, and the bars are the standard error of the mean. NS, not significant.

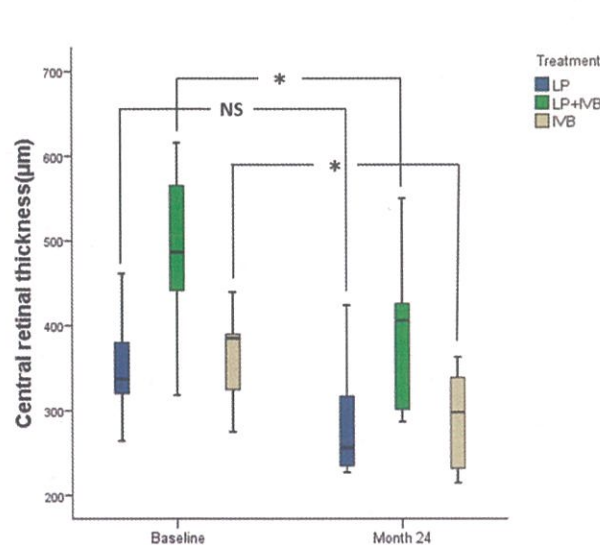


Fig. 2. Box plot of CRT according to treatment option at baseline and 24 months. The CRT of Type 1 IMT eyes treated with IVB and LP with IVB is significantly reduced at 24 months. The mean is the horizontal line, the boxes are the first/third quartiles, and the bars are the standard error of the mean. \*indicates  $P < 0.05$ , NS, not significant.

Table 3. Multiple Logistic Regression Model of Variables Associated With Retinal Vascular Events

	Standard		
	OR	95% CI	P
Sex	6.249	0.572–68.305	0.133
CRT at baseline	1.013	1.000–1.025	0.048
LogMAR	1.778	0.006–559.124	0.845
BCVA at baseline			
History of cerebral infarction	2.581	0.102–65.499	0.566
History of myocardial infarction	12.592	0.435–364.812	0.140

CI, confidence interval; OR, odds ratio.

Longitudinal analysis showed that sex, logMAR BCVA at baseline, cerebral infarction, and myocardial infarction were not correlated with any of the retinal vascular events. Only CRT at baseline was significantly correlated with retinal vascular events of Type 1 IMT ( $P = 0.048$ , Table 3).

The adverse event of RVO was not correlated with blood hypertension, myocardial infarction, or hyper-

lipidemia. The risk factors of RVO development were statistically significantly related to sex ( $P = 0.035$ ) and medical history of brain infarction ( $P = 0.031$ ). The number of IVB and LP administrations was not related to any of the factors.

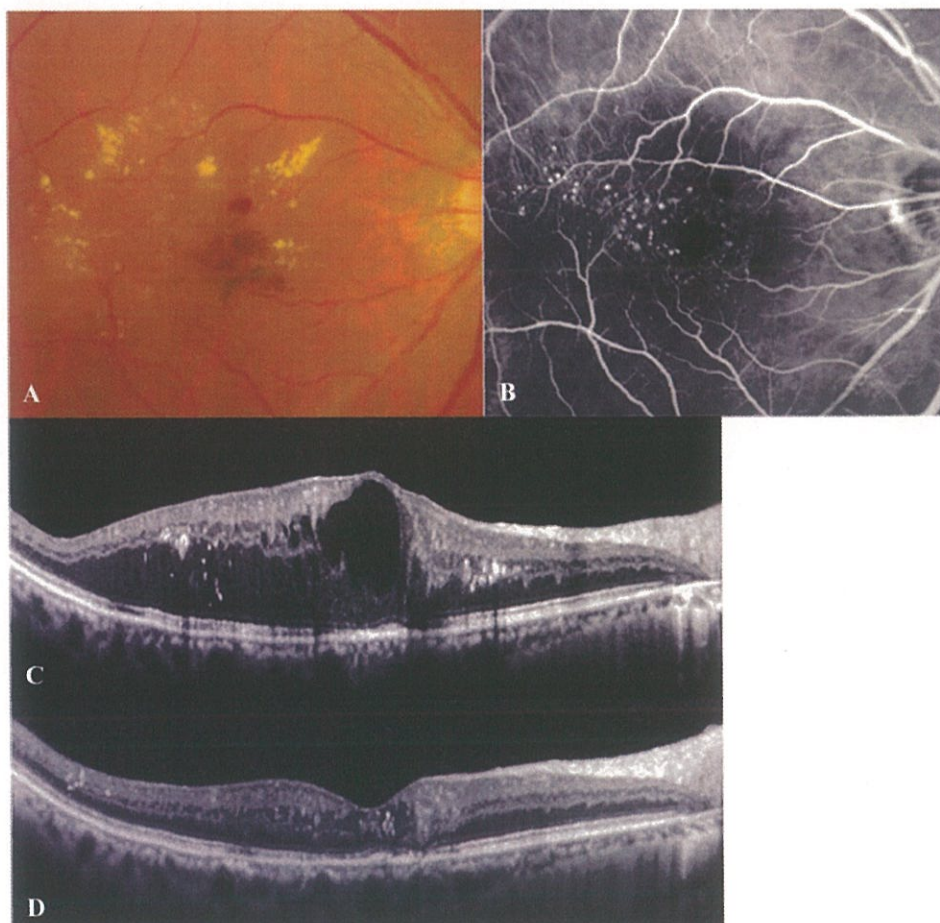*A 68-year-old man with Type 1 IMT in his right eye*

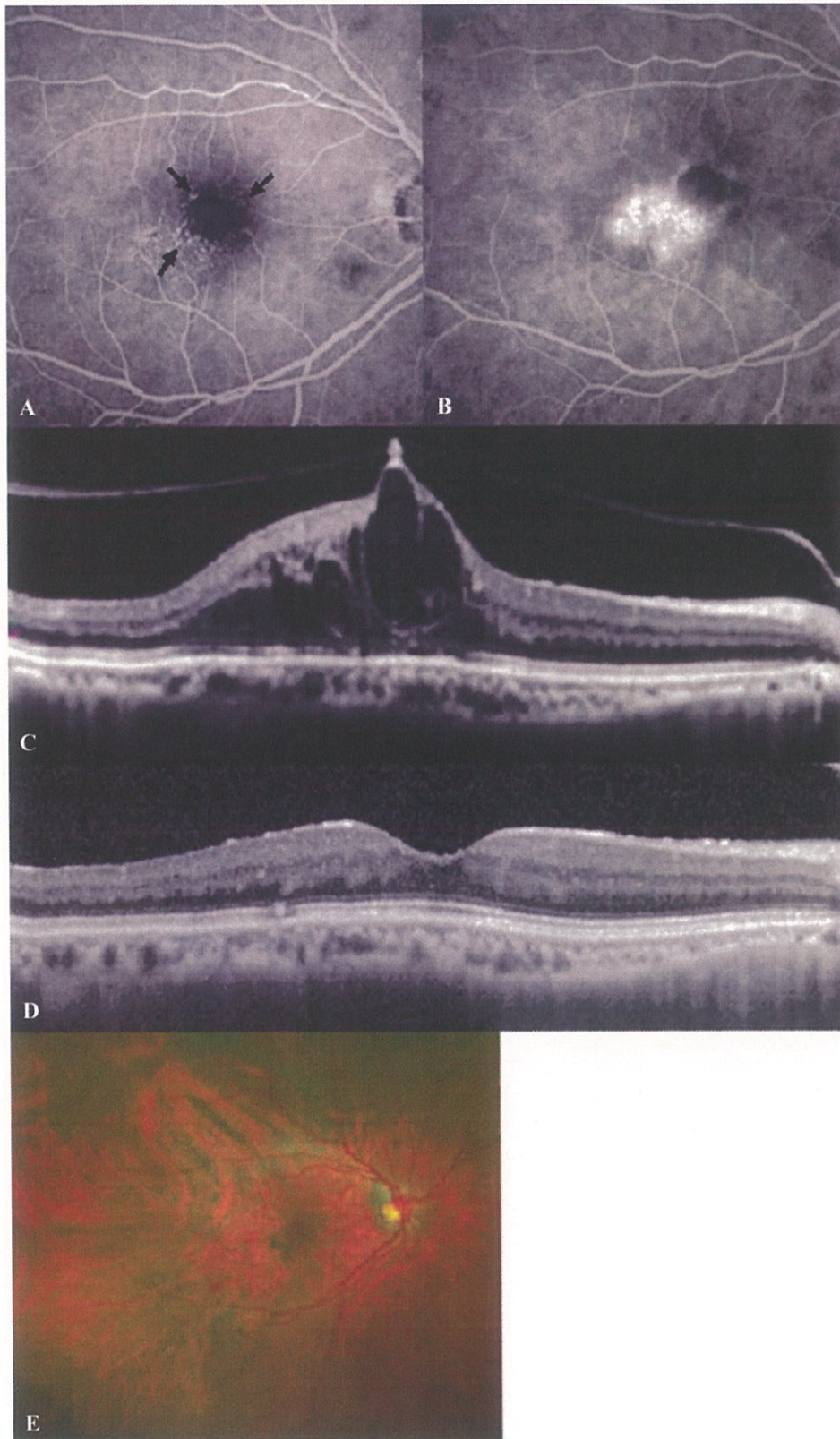
This patient was treated with LP alone in his right eye (Figure 3). His BCVA was 20/100, and CRT was 600  $\mu\text{m}$  at baseline. Cystoid macula edema decreased gradually after LP treatment. The BCVA improved to 20/40 and CRT reduced to 292  $\mu\text{m}$  at 24 months.

*A 72-Year-Old Woman With Type 1 Idiopathic Macula Telangiectasia in Her Right Eye*

This case was complicated with branch retina vein occlusion in the patient’s right eye during the treatment of Type 1 IMT (Figure 4). The patient was treated with IVB followed by LP. At baseline, BCVA was 20/50 and CRT was 543  $\mu\text{m}$ . After LP

**Fig. 3.** Case 1. A 68-year-old man with Type 1 IMT in his right eye treated with LP monotherapy. Color fundus photograph shows multiple MAs and retinal edema with hard exudates at the center of the macular area (A). Early-phase fluorescein angiography reveals parafoveal ectatic capillaries and MAs (B). Horizontal scan image of optical coherence tomography images at baseline show retinal thickening and cystoid spaces in the macular area (C). Optical coherence tomography image at 24 months shows that the intraretinal cystoid was reduced (D).





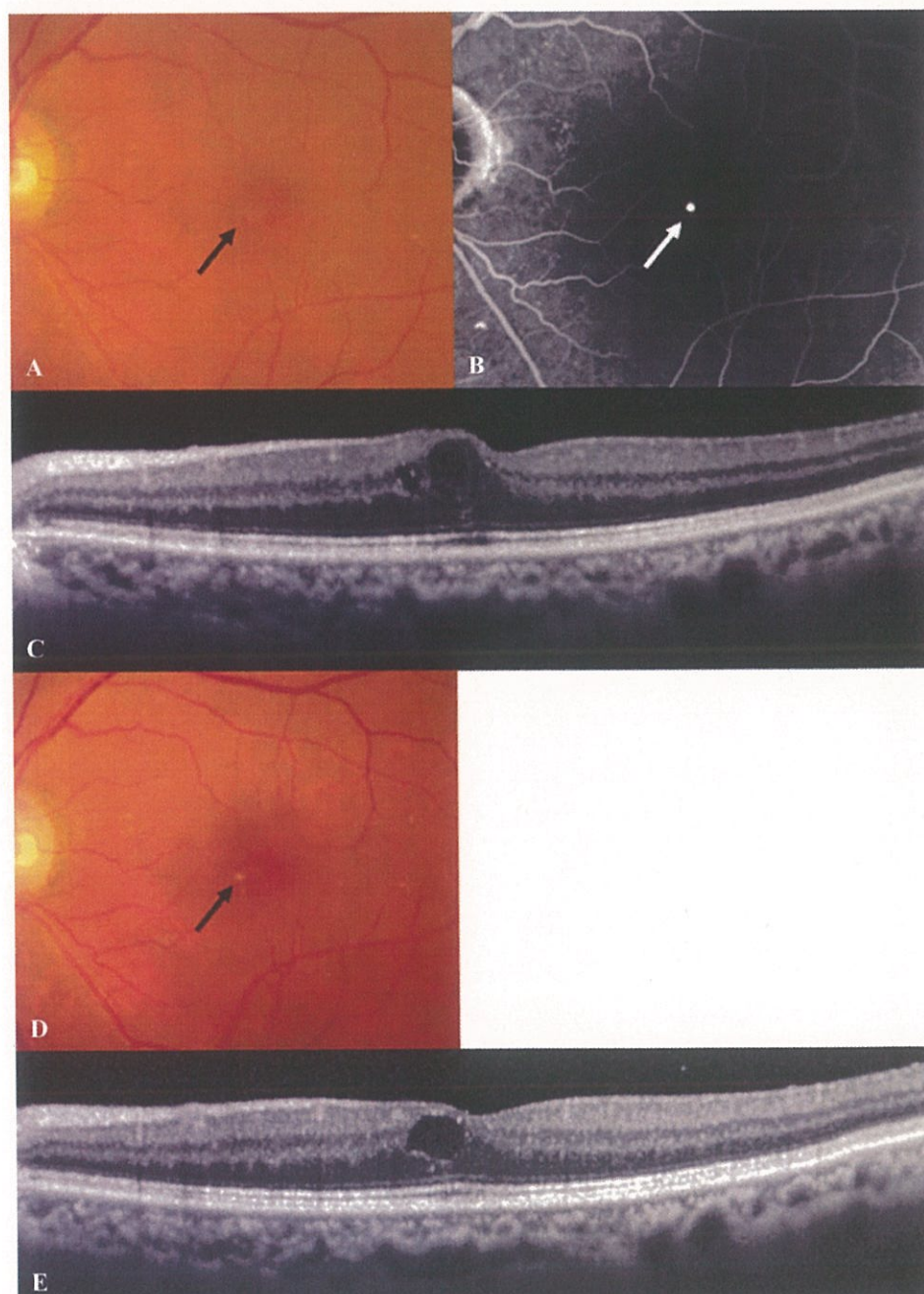
**Fig. 4.** Case 2. A 72-year-old woman with Type 1 IMT in her right eye treated with IVB followed by laser photocoagulation. Early-phase fluorescein angiography shows ectatic parafoveal capillary vessels and MAs (arrows) (A). Late-phase fluorescein angiography reveals late leakage (B). Optical coherence tomography image at baseline shows cystoid macular edema (C). Optical coherence tomography image at 24 months shows that the intraretinal cystoid has disappeared (D). Color fundus photograph reveals the occurrence of branch retinal vein occlusion at 24 months (E).

treatment followed by two IVB injections, BCVA stabilized, and macular edema disappeared. At 24 months, branch retinal vein occlusion occurred in the right eye.

*An 82-Year-Old Man With Type 1 Idiopathic Macula Telangiectasia in His Left Eye*

This patient was followed up without receiving treatment in his left eye (Figure 5). At baseline, his

BCVA was 20/25 and CRT was 331  $\mu\text{m}$ . Because his BCVA was better than 20/33, and his CRT was lower than 350  $\mu\text{m}$ , the eye was not treated, and the natural course was observed over 2 years. Microaneurysm color changed from reddish (arrow in Figure 5A) at baseline to whitish (arrow in Figure 5B) at 24 months. Twenty-four months after baseline, his BCVA was maintained at 20/25, and CRT was reduced to 302  $\mu\text{m}$ .



**Fig. 5.** Case 3. An 82-year-old man with Type 1 idiopathic macula telangiectasia in his left eye received no treatment. Color fundus photograph shows a reddish MA (arrow) and retinal edema at the center of the macular area (A). Early-phase fluorescein angiography reveals a parafoveal MA (arrow) (B). Horizontal scan image of optical coherence tomography image at baseline shows retinal thickening and cystoid spaces in the macular area (C). Color fundus photograph reveals a whitish MA (arrow) at 24 months (D). Optical coherence tomography image at 24 months shows that the macular edema reduced naturally (E).



### Discussion

In this study, we retrospectively evaluated the clinical features of treated and untreated Type 1 IMT eyes followed up for 2 years. There are no established treatments for Type 1 IMT and therapeutic possibilities are limited, although some patients respond to LP.<sup>5-7</sup> Only a few cases in which intravitreal triamcinolone was successfully used to treat macular edema related to Type 1 IMT have been reported.<sup>9,10</sup> Recently, several studies reporting the use of bevacizumab in the treatment of Type 1 IMT have been published; however, outcomes have been inconsistent.<sup>4,12-16</sup> Gamulescu et al<sup>8</sup> reported that a single IVB injection markedly increased VA in a Type 1 IMT patient, suggesting that anti-VEGF therapy may be effective at treating the associated visual deterioration. In other reports, the effect of bevacizumab seems to be limited in Type 1 IMT patients compared with Type 2 IMT patients.<sup>17</sup> VEGF treatment for Type 1 IMT is therefore controversial.

The reason for the discrepancies in the results of anti-VEGF therapy may be due to differences in treatment protocol. Takayama et al<sup>4</sup> reported a treatment protocol for Type 1 IMT as follows: if macular edema did not reduce, additional treatments were performed one to two times at the discretion of the physician at 4-week intervals after treatment. In contrast, Koay et al administered a monthly injection of IVB three times from baseline.<sup>13</sup> It is unknown whether VEGF has a function in the pathogenesis of Type 1 IMT. Vascular endothelial growth factor plays an integral part in the formation of abnormal blood vessels and in increasing vascular permeability in many pathologic conditions.<sup>17-19</sup> This suggests that late anti-VEGF therapy for long-lasting macular edema or/and edema recurrence produces good anatomical outcomes but does not improve vision. Because these conditions may lead to irreversible retinal damage, early treatment can have a beneficial effect on VA.

In this study, we evaluated the long-term treatment of Type 1 IMT with LP and/or IVB. Laser photocoagulation and/or IVB may be effective at treating macular edema. In the treatment group, BCVA improved in 5 cases and was maintained in 24 cases from baseline to 24 months. In one case treated with IVB monotherapy, this was not accompanied with an increase in VA. When LP is administered alone, if the MA or ectatic parafoveal capillary vessels are too close to the fovea, the following combined IVB therapy must be effective. Although, LP is effective at treating macula edema, recurrence can sometimes occur due to the reopening of capillary vessels or the

occurrence of new ectatic capillaries. Furthermore, repetition of LP may lead to parafoveal retinal scarring. Combination therapy with IVB reduces the number of required LP applications.

Some self-limiting eyes maintained good VA in this study, although there are no reports on the natural course of Type 1 IMT. This may be the indication for treatment, which was cases with Snellen BCVA of 20/33 or less, or CRT of at least 350  $\mu\text{m}$  at the initial visit. In fact, in 18 untreated eyes with Type 1 IMT, the mean VA was maintained and the mean CRT reduced significantly between baseline and 24 months. Watzke et al concluded that vision loss was associated with an increase in the extent of Type 1 IMT and intraretinal edema to the point of cyst formation.<sup>20</sup> It is important that the VA is improved, and CME slightly improved compared with that at baseline.

Retinal vascular adverse events were observed in seven eyes (14.3%) with Type 1 IMT over the 2-year follow-up period. These retinal events were significantly associated with CRT at baseline. The mechanism of Type 1 IMT pathogenesis appeared to be correlated with other retinal vascular events. Actually, the risk factors of RVO development were statistically significantly related to sex (women) and medical history of cerebral infarction, whereas the number of IVB administrations and LP was not related to any factor. Therefore, during the follow-up period for Type 1 IMT, patient sex and medical history of cerebral infarction must be taken into consideration for the development of other retinal complications, especially RVO.

In conclusion, LP and/or IVB may be effective at treating Type 1 IMT, although treatment was not required over a 2-year follow-up in some cases (36.7%). Furthermore, regardless of the presence or absence of systemic disease, other retinal vascular events were not uncommon in Type 1 IMT. Because this study was retrospective and of a small size, further studies are necessary to confirm findings and to further clarify the clinical significance of visual prognosis in patients with Type 1 IMT.

**Key words:** Type 1 idiopathic macular telangiectasia, macular edema, intravitreal anti-vascular endothelial growth factor, intravitreal bevacizumab, laser photocoagulation, retinal vein occlusion, retinal macroaneurysm, vascular permeability.

### References

1. Gass JD, Blodi BA. Idiopathic juxtafoveal retinal telangiectasis. Update of classification and follow-up study. *Ophthalmology* 1993;100:1536-1546.
2. Yannuzzi LA, Bardal AM, Freund KB, et al. Idiopathic macular telangiectasia. *Arch Ophthalmol* 2006;124:450-460.

3. Maruko I, Tada T, Sugano Y, et al. Demographic features of idiopathic macular telangiectasia in Japanese patients. *Jpn J Ophthalmol* 2012;56:152–158.
4. Takayama K, Ooto S, Tamura H, et al. Intravitreal bevacizumab for type 1 idiopathic macular telangiectasia. *Eye (Lond)* 2010;24:1492–1497.
5. Chopdar A. Retinal telangiectasis in adults: fluorescein angiographic findings and treatment by argon laser. *Br J Ophthalmol* 1978;62:243–250.
6. Hirano Y, Yasukawa T, Usui Y, et al. Indocyanine green angiography-guided laser photocoagulation combined with sub-Tenon's capsule injection of triamcinolone acetonide for idiopathic macular telangiectasia. *Br J Ophthalmol* 2010;94:600–605.
7. Steigerwalt RD Jr, Pascarella A, Arrico L, et al. Idiopathic juxtafoveal retinal telangiectasis and retinal macroaneurysm treated with indocyanine green dye-enhanced photocoagulation. *Panminerva Med* 2012;54:93–96.
8. Garmulescu MA, Walter A, Sachs H, Helbig H. Bevacizumab in the treatment of idiopathic macular telangiectasia. *Graefes Arch Clin Exp Ophthalmol* 2008;246:1189–1193.
9. Sandali O, Akesbi J, Rodallec T, et al. Dexamethasone implant for the treatment of edema related to idiopathic macular telangiectasia. *Can J Ophthalmol* 2013;48:e78–e80.
10. Cakir M, Kapran Z, Basar D, et al. Optical coherence tomography evaluation of macular edema after intravitreal triamcinolone acetonide in patients with parafoveal telangiectasis. *Eur J Ophthalmol* 2006;16:711–717.
11. Moon BG, Kim YJ, Yoon YH, Lee JY. Use of intravitreal bevacizumab injections to treat type 1 idiopathic macular telangiectasia. *Graefes Arch Clin Exp Ophthalmol* 2012;250:1697–1699.
12. De Bats F, Denis P, Kodjikian L. [Idiopathic macular telangiectasia: clinical appearance, imaging and treatment]. *J Fr Ophthalmol* 2013;36:164–171.
13. Koay CL, Chew FL, Visvaraja S. Bevacizumab and type 1 idiopathic macular telangiectasia. *Eye (Lond)* 2011;25:1663–1665. author reply 1665.
14. Matsumoto Y, Yuzawa M. Intravitreal bevacizumab therapy for idiopathic macular telangiectasia. *Jpn J Ophthalmol* 2010;54:320–324.
15. Moon SJ, Berger AS, Tolentino MJ, Misch DM. Intravitreal bevacizumab for macular edema from idiopathic juxtafoveal retinal telangiectasis. *Ophthalmic Surg Lasers Imaging* 2007;38:164–166.
16. Green WR, Quigley HA, De la Cruz Z, Cohen B. Parafoveal retinal telangiectasis. Light and electron microscopy studies. *Trans Ophthalmol Soc U K* 1980;100:162–170.
17. Okamoto N, Tobe T, Hackett SF, et al. Transgenic mice with increased expression of vascular endothelial growth factor in the retina: a new model of intraretinal and subretinal neovascularization. *Am J Pathol* 1997;151:281–291.
18. Kamat BR, Brown LF, Manseau EJ, et al. Expression of vascular permeability factor/vascular endothelial growth factor by human granulosa and theca lutein cells. Role in corpus luteum development. *Am J Pathol* 1995;146:157–165.
19. Pierce EA, Avery RL, Foley ED, et al. Vascular endothelial growth factor/vascular permeability factor expression in a mouse model of retinal neovascularization. *Proc Natl Acad Sci U S A* 1995;92:905–909.
20. Watzke RC, Klein ML, Folk JC, et al. Long-term juxtafoveal retinal telangiectasia. *Retina* 2005;25:727–735.